

ANGLE CLOSURE IN YOUNGER PATIENTS

BY Brian M. Chang, MD (BY INVITATION), Jeffrey M. Liebmann, MD (BY INVITATION), AND Robert Ritch, MD

ABSTRACT

Purpose: Angle-closure glaucoma is rare in children and young adults. Only scattered cases associated with specific clinical entities have been reported. We evaluated the findings in patients in our database aged 40 or younger with angle closure.

Methods: Our database was searched for patients with angle closure who were 40 years old or younger. Data recorded included age at initial consultation; age at the time of diagnosis; gender; results of slit-lamp examination, gonioscopy, and ultrasound biomicroscopy (from 1993 onward); clinical diagnosis; and therapy. Patients with previous incisional surgery were excluded, as were patients with anterior chamber proliferative mechanisms leading to angle closure.

Results: Sixty-seven patients (49 females, 18 males) met entry criteria. Mean age (\pm SD) at the time of consultation was 34.4 ± 9.4 years (range, 3-68 years). Diagnoses included plateau iris syndrome (35 patients), iridociliary cysts (8 patients), retinopathy of prematurity (7 patients), uveitis (5 patients), isolated nanophthalmos (3 patients), relative pupillary block (2 patients), Weill-Marchesani syndrome (3 patients), and 1 patient each with Marfan syndrome, miotic-induced angle closure, persistent hyperplastic primary vitreous, and idiopathic lens subluxation.

Conclusion: The etiology of angle closure in young persons is different from that in the older population and is typically associated with structural or developmental ocular anomalies rather than relative pupillary block. Following laser iridotomy, these eyes should be monitored for recurrent angle closure and the need for additional laser or incisional surgical intervention.

Trans Am Ophthalmol Soc 2002;100:201-214

INTRODUCTION

Angle-closure glaucoma is a disease of older persons. The incidence of primary angle closure, about 90% of which, in the United States, results from relative pupillary block, increases with age, peaking between the ages of 55 and 70 years and then declining. Angle closure is rare in children and young adults, only isolated cases and small series, primarily composed of particular entities, having been reported.¹⁻¹⁴ The purpose of this study was to evaluate the demographics and clinical information for all patients in our database with angle closure who were 40 years old or younger.

PATIENTS AND METHODS

We chose age 40 as an arbitrary cutoff to define "younger" patients as being under the age of onset of presbyopia. Eligible patients were those having presented with

histories, symptoms, and findings characteristic of acute, subacute, or intermittent angle closure, chronic angle closure with peripheral anterior synechiae (PAS), or appositionally closed angles on the basis of gonioscopy or ultrasound biomicroscopic dark room provocative testing. We reviewed our database of approximately 14,000 patients for patients aged 40 years or younger at the time of initial diagnosis who fulfilled these criteria.

The following data were extracted from the medical record: date of birth, gender, clinical diagnoses, age at diagnosis of angle closure, age at time of initial consultation with us, manifest refraction (converted to spherical equivalent), axial length (when available), therapeutic intervention (medical treatment, laser iridotomy, laser iridoplasty, incisional surgery), ultrasound biomicroscopy (UBM, from 1993 onward), and the mechanism underlying the angle closure. These were classified as pupillary block, plateau iris (and pseudoplateau iris), and lens-induced angle closure. Patients with a previous history of intraocular surgery (aphakic or pseudophakic pupillary block or malignant glaucoma) were excluded, as were patients with purely anterior proliferative mechanisms,¹⁵ leading to formation of PAS due to pathology at the level of the iris or iridocorneal angle.

From the Departments of Ophthalmology, the New York Eye and Ear Infirmary, New York, New York, and the New York Medical College, Valhalla, New York. Supported by the Donald Engel Research Fund of the New York Glaucoma Research Institute.

RESULTS

Sixty-seven patients (0.48% of the patients in our database) met the entry criteria. These represented 2.34% of the 2,864 patients with angle closure in the database at the time of extraction. There were 49 females (73.1%) and 18 males (26.9%). The mean age \pm SD at the time of diagnosis of angle closure was 31.3 ± 8.5 years (range, 3-40 years), while the mean age at the time of our initial consultation was 34.4 ± 9.4 years (range, 3-68 years). The ages at diagnosis were 0 to 10 years (3 patients), 11 to 20 years (3 patients), 21 to 30 years (12 patients), and 31 to 40 years (49 patients). All patients older than age 40 at the time of initial consultation had been diagnosed as having angle closure prior to age 40. Some patients had been referred for UBM imaging only, resulting in incomplete historical information or incomplete refractive or biometric data, or both.

The patient diagnoses and demographics are listed in Table I. Plateau iris syndrome was the most common diagnosis, accounting for 35 (52.2%) of the patients in our series. The mean age of these patients at the time of diagnosis was 34.9 ± 4.6 years (range, 23-40 years). Twenty-six (74.3%) were female. Six had presented with acute angle closure. Mean refractive error was $+1.94 \pm 0.4$ diopters OD and $+1.74 \pm 1.8$ diopters OS. Laser iridotomy was

performed or recommended in 69 of the 70 eyes. Twenty-seven eyes received argon laser peripheral iridoplasty (ALPI) for persistent appositional closure after iridotomy, and the remaining patients (43 eyes) were either referred back to their primary ophthalmologists or maintained under observation.

Eight patients (11.9%, 7 female, 1 male) had iridociliary cysts. The mean age at diagnosis was 29.0 ± 9.3 years (range, 14-40 years). No patient presented with a history of acute angle closure. These eyes presented clinically as plateau iris, with a prominent double hump sign, and the diagnosis was made by UBM. Indentation gonioscopy in some cases in which cyst distribution was irregular provided a tentative diagnosis. Thirteen of these 16 eyes underwent laser iridotomy. Of the remaining three eyes, one had no cysts and an open angle, and two had open angles with cysts and only small areas of appositional closure. Only four eyes went on to require ALPI because of continued appositional closure after iridotomy.

Seven patients (11 eyes) were nanophthalmic (Table II). The mean refractive error of affected eyes in the seven patients was -1.3 ± 6.5 diopters (range, -9.00 to +4.00). The axial lengths ranged from 17.0 to 20.35 mm. Three patients had isolated nanophthalmos OU. The mean age at the time of diagnosis of angle closure in these patients was 28.7 ± 4.9 years (range, 23-32 years). All six

TABLE I: DEMOGRAPHICS OF STUDY GROUP

DIAGNOSIS	NO. OF PATIENTS	MEAN AGE (YR) (RANGE)	GENDER
Plateau iris syndrome	35/67 (52.2%)	34.9 ± 4.6 (23-40)	9/36 M (25.7%) 26/36 F (74.3%)
Iridociliary cysts	8/67 (11.9%)	29.0 ± 9.3 (14-40)	1/8 M (12.5%) 7/8 F (87.5%)
Retinopathy of prematurity	7/67 (10.4%)	24.3 ± 13.5 (3-37)	2/7 M (28.6%) 5/7 F (71.4%)
Uveitis	5/67 (7.5%)	34.2 ± 2.3 (32-38)	3/5 M (60%) 2/5 F (40%)
Nanophthalmos	3/67 (4.5%)	16.7 ± 12.5 (5-30)	1/3 M (33.3%) 2/3 F (66.7%)
Relative pupillary block	2/67 (3.0%)	37.5 ± 3.5 (35-40)	2/2 F
Weill-Marchesani	3/67 (4.4%)	26.5 ± 3.6 (18-30)	1/3 M 2/3 F
Marfan syndrome	1/67 (1.5%)	20	1/1 F
Miotic-induced angle closure	1/67 (1.5%)	20	1/1 M
Persistent hyperplastic primary vitreous	1/67 (1.5%)	24	1/1 F
Lens subluxation	1/67 (1.5%)	36	1/1 F

Angle Closure in Younger Patients

TABLE II: COEXISTING DIAGNOSES, AXIAL LENGTH, AND REFRACTION IN EYES WITH NANOPHTHALMOS

DIAGNOSIS	AXIAL LENGTH OD/OS (MM)	MEAN SPHERICAL EQUIVALENT OD/OS (D)	COMMENTS
Nanophthalmos	NA/20	+2.75/+2.75	OD excluded from analysis
Nanophthalmos	17/19	NA/NA	
Nanophthalmos	19.7/20	+3.75/+3.5	
Nanophthalmos and Weill Marchesani	19.64/19.48	-9.00/-8.75	
Nanophthalmos and Weill Marchesani	20.25/20.35	-7.75/-8.25	
Nanophthalmos and plateau iris	20.8/20.15	+4.00/+4.00	OD excluded from analysis
Nanophthalmos and ROP	21.46/19.94	NA/NA	OD excluded from analysis

NA, not available; ROP, retinopathy of prematurity.

eyes underwent laser iridotomy. One eye subsequently had ALPI. Of the four patients in other diagnostic categories who were also nanophthalmic in one or both eyes, all six of the nanophthalmic eyes underwent both laser iridotomy and ALPI.

Two patients, aged 35 and 40 years at the time of diagnosis, had relative pupillary block as determined by UBM evaluation. There was no evidence of plateau iris configuration or syndrome on gonioscopy or UBM evaluation (Figure 1). Axial lengths were not obtained.

Seven patients (10.4%) had retinopathy of prematurity (ROP). The mean age at the time of diagnosis of angle closure was 24.3 ± 13.5 years (range, 3-37 years). Mean refractive error was -6.5 ± 11.7 diopters OD and -6.24 ± 10.7 diopters OS. One eye was nanophthalmic. Five eyes of five patients had presented initially with acute angle closure. Four patients were initially treated with surgical iridectomies or laser iridotomy and then required ALPI for intraocular pressure (IOP) control. Iridotomy was per-

formed in one patient, without additional need for ALPI. Iridotomy was recommended in one patient. Six eyes eventually underwent incisional surgery for additional pressure control.

Five patients (7.4%; 3 male, 2 female, 6 eyes) had uveitis and angle closure secondary to absolute pupillary block. Their mean age at the time of diagnosis was 34.2 ± 2.3 years. All affected eyes underwent laser iridotomy, and none required ALPI.

Two patients, a brother who presented with acute angle closure and his sister, whose angle closure was detected on examination, had Weill-Marchesani syndrome and nanophthalmos with angle closure secondary to anterior lens subluxation. These patients, both successfully treated with ALPI after iridotomies, have been previously reported.¹⁶ One additional patient had Weill-Marchesani syndrome and was aphakic in her only eye on presentation to us. One patient had Marfan syndrome and presented with chronic angle closure. Her refractive error was -17.00 and -13.25 diopters (spherical equivalent) with axial lengths of 24.71 and 23.59 mm, respectively.

One patient had persistent hyperplastic primary vitreous. One had a history of trauma at age 3 and developed acute angle closure in that eye after undergoing general anesthesia. Laser iridotomy and iridoplasty were required to control the IOP until the lens could be removed. One had miotic-induced angle closure and responded to elimination of the pilocarpine. Of the 17 patients who had a history of acute angle closure, 6 had plateau iris, 5 had ROP, 2 had uveitis, 2 had Weill-Marchesani syndrome, 1 had miotic-induced angle closure, and 1 had a subluxed lens after trauma.

DISCUSSION

Angle closure is an anatomic disorder characterized by iris

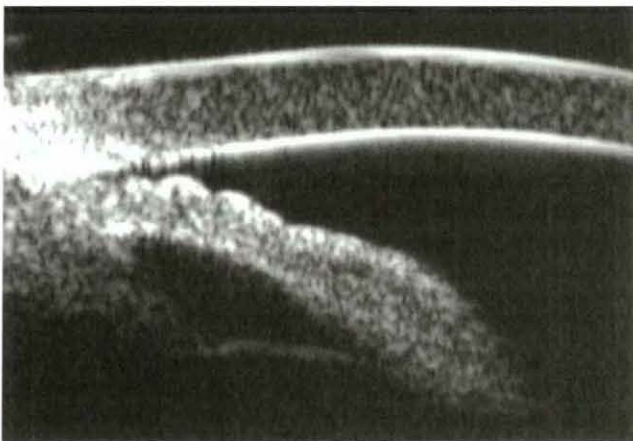


FIGURE 1

Pupillary block in 35-year-old woman. Iris contour is convex, posterior chamber is distended, and prominent ciliary sulcus is present.

apposition to the trabecular meshwork and is caused by abnormalities in the relative or absolute sizes or positions of anterior segment structures and/or anteriorly directed pressure in the posterior segment.¹⁷ The forces posterior to the iris that lead to this situation can be conceived of as originating at four structural levels. Going from anterior to posterior, these consist of increased aqueous pressure in the posterior chamber (relative or absolute pupillary block), anatomic variations of the ciliary body (plateau iris and iridociliary cysts), the lens (phacomorphic glaucoma), and forces posterior to the lens (malignant glaucoma).

PUPILLARY BLOCK

Pupillary block is defined as impedance to the flow of aqueous humor from the posterior to the anterior chamber between the anterior surface of the lens and the posterior surface of the iris and is divided into relative (without posterior synechiae) and absolute (secondary to posterior synechiae) pupillary block. The ciliary sulcus is present. Indentation gonioscopy easily opens the peripheral angle because of the lack of resistance in the posterior chamber. Approximately 90% of patients with angle closure have relative pupillary block as the underlying mechanism.

Relative pupillary block typically occurs in hyperopic eyes, which have a shorter-than-average axial length, a more shallow anterior chamber, a thicker lens, a more anterior lens position, and a smaller radius of corneal curvature.¹⁸⁻²² Angle closure caused by relative pupillary block is a disease of middle-aged and older individuals. Laser iridotomy provides the definitive treatment and results in an open angle (Figure 1).

Although many of our patients with plateau iris syndrome had an element of pupillary block, only two were deemed to have pure pupillary block based on clinical and UBM findings. Both underwent laser iridotomy with successful opening of the angle. The anterior chamber decreases in depth and volume with age.²³⁻²⁷ Continued growth of the lens during adult life results in about 0.75 to 1.1 mm increased thickness and about 0.4 to 0.6 mm forward movement of the anterior lens surface.^{18-20,28} The ratio of lens thickness to axial length increases with age and is greater in patients with angle closure.²⁹ Patients younger than age 40 would be least expected to exhibit these changes.

PLATEAU IRIS

Plateau iris is defined as an angle appearance in which the iris root angulates forward and then centrally³⁰ (Table III). The iris root is often short and inserted anteriorly on the ciliary face, so that the angle is shallow and narrow, with a sharp drop-off of the peripheral iris at the inner aspect of the angle. Classically, the iris configuration is planar and

the anterior chamber depth within the normal range. In older individuals, in whom the lens is larger and the anterior lens surface more anterior, the iris contour may be rounded, particularly when pupillary block is also present.

Plateau iris syndrome is diagnosed on the basis of continued appositional closure after laser iridotomy accompanied by a double hump sign on indentation gonioscopy and may be either complete (closure to the level of Schwalbe's line, resulting in elevated IOP) or incomplete (closure to a lower level on the trabecular meshwork so that IOP does not rise but PAS may develop over time with continued apposition).^{17,31-33} Ultrasound biomicroscopy reveals anteriorly positioned ciliary processes and the absence of a ciliary sulcus (Figure 2).^{34,35} The ciliary body position accounts for the double hump sign seen gonioscopically (Figure 3). This configuration persists after cataract extraction.³⁶ The definitive treatment for plateau iris is ALPI (Figure 4).^{37,38}

Patients with plateau iris tend to be female and to be younger and less hyperopic than those with relative pupillary block, and they often have a family history of angle-closure glaucoma. Except in the youngest patients, some element of pupillary block is usually present. Iridotomy may result in an open angle (plateau iris configuration) or continue appositional closure either spontaneously or with pharmacologic dilation (plateau iris syndrome). In the former case, periodic gonioscopy is indicated, because the angle can narrow further with age due to enlargement of the lens, leading to PAS formation.

Plateau iris was the most common underlying etiology in our patients. There was a clear female preponderance (74.3%). Their mean age was notably younger than that described in the literature for angle closure secondary to relative pupillary block. Six patients (17.1%) had presented with acute angle closure. All eyes but one underwent laser iridotomy. We could not assess the total number of patients requiring ALPI, because many were seen in consultation and laser treatment had been performed elsewhere.

IRIDOCILIARY CYSTS

Iridociliary cysts can push the iris root anteriorly, causing a pseudoplateau configuration with or without angle closure (Figure 5). When large or extensive, they may produce angle closure³⁹⁻⁴⁶ (Table IV). In a UBM study of 90

TABLE III: REPORTED CASES OF ANGLE CLOSURE WITH PLATEAU IRIS SYNDROME

AUTHORS	YEAR	AGE AT DIAGNOSIS	JACG/CASES REPORTED
Tomquist ³⁰	1958	44	0/1
Wand <i>et al</i> ³¹	1977	37-84 yr	2/8

JACG, juvenile angle closure glaucoma.

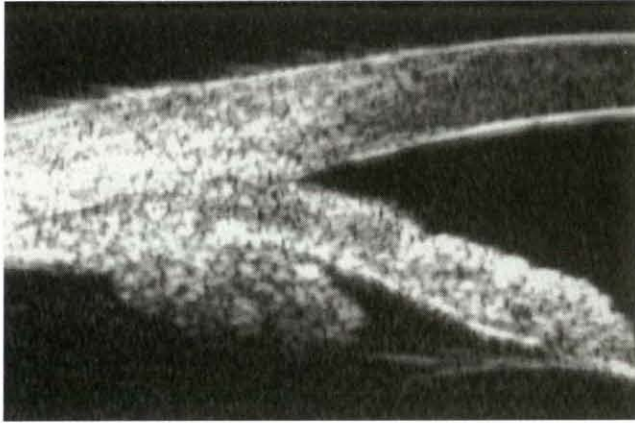


FIGURE 2

Plateau iris syndrome after laser iridotomy. Angle remains closed, anterior chamber is relatively deep, iris contour is essentially planar, posterior chamber is very small, ciliary processes are markedly centrally displaced, and no ciliary sulcus is present.

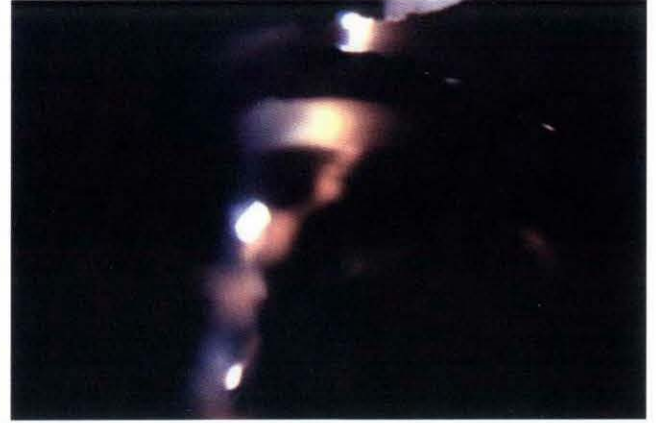

FIGURE 3

Double hump sign in eye with plateau iris. Beam follows curvature of iris over lens, reaches its deepest point at level of posterior chamber, then curves up again over ciliary processes.

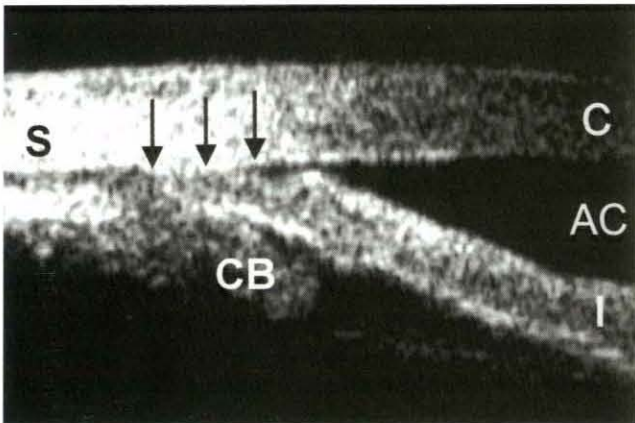


FIGURE 4A

Ultrasound biomicroscopy of eye with plateau iris syndrome before argon laser peripheral iridoplasty. Angle is closed to Schwalbe's line (arrows). S, sclera; CB, ciliary body; I, iris; AC, anterior chamber; C, cornea.

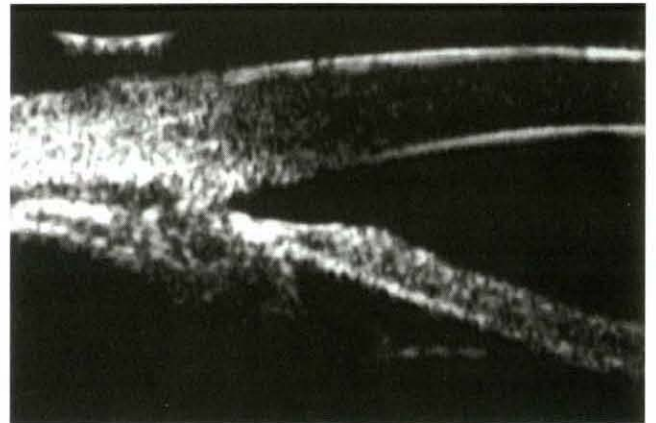


FIGURE 4B

Ultrasound biomicroscopy of eye with plateau iris syndrome after argon laser peripheral iridoplasty. Peripheral iris stroma has been compacted, creating an open angle.

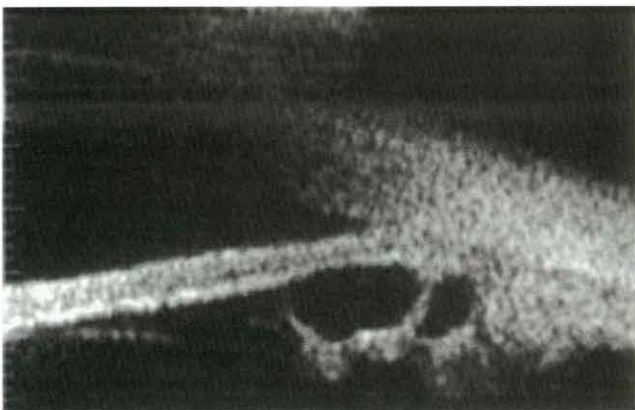


FIGURE 5

Iridociliary cysts causing angle closure with a pseudoplateau iris configuration.

eyes with primary neuroepithelial cysts, more than three cysts per eye were found in 34 eyes (37.8%).⁴⁵ Shields and associates¹¹ reviewed the findings in 44 children with primary iris pigment epithelial cysts, 34 of whom had iridociliary cysts. The cyst was usually detected on slit-lamp examination as bulging of the peripheral iris, and the patient was referred to rule out a tumor. In contrast, iridociliary cysts causing angle closure in our patients were multiple, extended around the circumference of the angle, produced a double hump sign on indentation gonioscopy, and were usually detected by UBM. All patients required laser iridotomy in at least one eye. Four eyes of three patients had persistent appositional closure after iridotomy and were successfully treated with ALPI.

LENS-INDUCED ANGLE CLOSURE

Block originating from enlargement or forward movement

TABLE IV: REPORTED CASES OF ANGLE CLOSURE AND IRIDOCILIARY BODY CYSTS

AUTHORS	YEAR	AGE AT DIAGNOSIS	JACG/CASES REPORTED	COMMENTS
Chandler and Braconier ¹¹⁴	1958			
Vela et al ³⁰	1984	36 yr	1/11	
Shields et al ¹¹⁵	1984	NA	0/62	No glaucoma in this series
Bron et al ⁴²	1984	28 yr	1/1	
Azuara-Blanco et al ⁴¹	1996	58-70 yr	0/3	Plateau iris and cysts as combined mechanism for closure
Tanihara et al ⁴⁰	1997	39 yr	1/1	
Lois et al ¹¹⁶	1998	7 mo - 70 yr	3/254	Chronic angle closure
Shields et al ¹¹	1999	<20 yr	0/251	Review of iris/ciliary body cysts in children; no separate analysis for glaucoma
Kuchenbecker et al ⁴⁴	2000	55 yr	0/1	
Viestenz et al ⁴³	2000	23 yr	1/1	Angle closure after mydriasis

JACG, juvenile angle closure glaucoma; NA, not available.

of the lens forces the ciliary body and iris anteriorly, closing the angle. The term *phacomorphic glaucoma* is traditionally reserved for angle closure caused by a large or intumescent lens. Indentation gonioscopy may be difficult or impossible to perform successfully. Angle closure associated with anterior lens subluxation or dislocation can occur with various syndromes that affect zonular integrity or after trauma. Indentation gonioscopy in these eyes reveals a dome-shaped central iris following the contour of the lens to its periphery and then leveling off in a flat plane to its insertion (Figure 6).

NANOPHTHALMOS

Nanophthalmos is a statistically derived definition and represents the short end of the spectrum of axial lengths. Isolated nanophthalmos is a bilateral, often familial form of microphthalmos unaccompanied by other congenital

malformations.⁴⁷ It is characterized by hyperopia, small corneal diameter, thick sclera, and narrow angles.⁴⁸ The axial length is between 14 and 20.5 mm, while the lens is of normal size, leading to a crowded anterior segment and a shallow anterior chamber.⁴⁹ The ratio of lens volume to ocular volume is four to eight times larger than that of normal eyes.⁵⁰ The sclera is characterized by abnormally packed, frayed, and disordered collagen fibers, loss of elastin, and an abnormal accumulation of glycosaminoglycans.⁵¹⁻⁵⁹ Uveal effusion is common, either spontaneously or after laser and surgical procedures.⁶⁰⁻⁶⁵ Nanophthalmos has been described in association with retinitis pigmentosa with or without cystic macular degeneration or optic nerve head drusen⁶⁶⁻⁶⁹ and Hallermann-Streiff syndrome.⁵⁶

There is an inverse correlation between the degree of hyperopia and the age at onset of angle closure, which usually develops between ages 20 and 50 (Table V). The

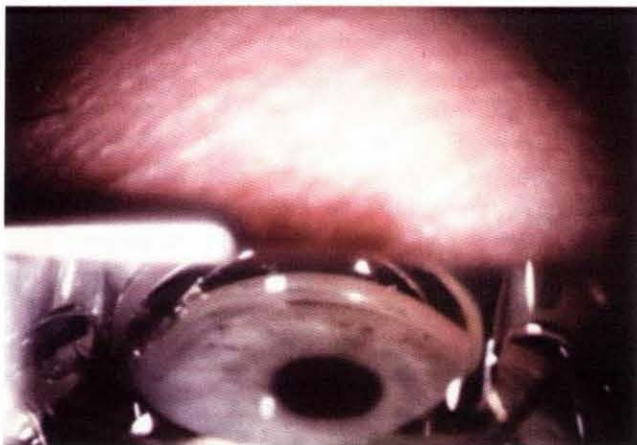

FIGURE 6A

Lens-induced angle closure. After iridotomy, angle remains closed without indentation. Black pigment at 12-o'clock position serves as reference point for Figure 6B.

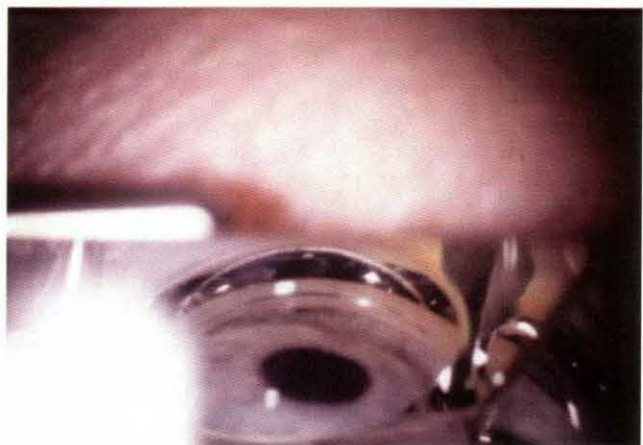


FIGURE 6B

Lens-induced angle closure. With indentation, iris follows contour of lens until it reaches posterior chamber, then has a planar configuration to its insertion

TABLE V: REPORTED CASES OF ANGLE-CLOSURE GLAUCOMA AND NANOPHTHALMOS

AUTHORS	YEAR	AGE AT DIAGNOSIS	JACG/CASES REPORTED	COMMENTS
O'Grady ⁴⁵	1971	23 yr	1/1	
Calhoun ¹⁰⁵	1975	31 yrs	1/6	
Brockhurst ⁴⁰	1975	30-51 yr	1/5	
Kimbrough et al ¹⁰⁶	1979	55-58 yr	0/2	
Singh et al ⁵⁰	1982	19-69 yr	14/16	
Ghose et al ¹⁰⁸	1985	56 yr	0/1	Nanophthalmos with pigmentary retinopathy
Diehl et al ¹⁰⁷	1989	64-72 yr	0/2	Coexisting diagnosis of pseudoexfoliation in 1 patient
Kocak et al ¹⁰⁸	1996-1997	Mean age, 14.6 yr	8/22 eyes	
Flowers et al ¹⁰⁹	1996	65 yr	0/1	Intraoperative air bubble leading to angle closure
Caronia et al ¹¹⁰	1998	80 yr	0/1	
Othman et al ¹¹¹	1998	7-77 yr	12/22	

JACG, juvenile angle closure glaucoma.

youngest reported patient with acute angle closure was a 9-year-old with 21 diopters of hyperopia.⁷⁰ Examination of families of affected individuals can permit detection of presymptomatic patients in early childhood.⁷¹ However, acute angle closure can also develop in the elderly.⁷²

Three of our patients had isolated nanophthalmos. All required iridotomy. Four other patients also had nanophthalmos, the two with Weill-Marchesani syndrome, one with ROP, and one eye of one patient with plateau iris (the other eye had an axial length of 20.8 mm).

RETINOPATHY OF PREMATURITY

Retinopathy of prematurity occurs primarily in infants with gestational age of less than 30 weeks or 1,500 g birth weight, or both. Incomplete growth of the peripheral posterior segment vasculature leads to areas of avascular retina. Cicatricial changes may ultimately lead to retinal detachment. Retrolental fibrovascular proliferation may lead to secondary angle closure, a well-known complication of the later stages and a major cause of poor vision (Table VI).^{73,74} Progressive lenticular myopia is often associated with shallowing of the anterior chamber.^{75,76} Angle closure has also been reported to occur after diode laser treatment for the retinopathy⁷⁷ and after scleral buckling.⁶

Angle closure may occur in very young children with ROP due to anterior displacement of the lens-iris diaphragm.^{8,78-82} These eyes do not respond to iridotomy or iridectomy.⁸³ In young adults with ROP, there may be a superimposed element of pupillary block, and iridotomy may be successful.^{84,85} Chronic angle closure may develop in adults.^{9,79,85} Iris vascular congestion may be present, mimicking neovascular glaucoma.⁸⁶

In one series of 26 untreated eyes with stage IV or V ROP, 3 had angle closure for over 180°, 15 had a highly convex iris, and 16 had posterior synechiae.⁸⁷ Microphthalmos may occur in eyes with ROP and may

also predispose to chronic angle-closure glaucoma.⁸⁸ Lens extraction alone or combined with vitrectomy has been recommended.^{4,8,73,79,80,82,89} We have found that ALPI may be beneficial in compacting the peripheral iris stroma and opening the angle in these patients.

Seven of our patients had ROP. Two patients evaluated by UBM demonstrated peripheral retinal membranes to the pars plana with peripheral vitreoretinal condensation (Figure 7). Contraction of these membranes may cause forward movement of the lens-iris diaphragm.

UVEITIS

Formation of posterior synechiae can lead to a secluded pupil and absolute pupillary block. Treatment includes medical management of both intraocular inflammation and elevated IOP. Iridotomy may be required to relieve a pupillary block component. In the case of significant posterior synechiae, multiple iridotomies may need to be performed to relieve segmental pupillary block.

Five of our patients (six eyes) had uveitis with angle closure secondary to total posterior synechiae. All

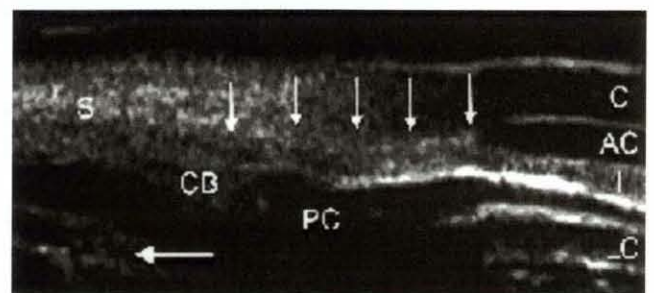


FIGURE 7

Retinopathy of prematurity. Lens (LC, lens capsule) is anteriorly displaced, anterior chamber (AC) is extremely shallow, and angle sealed with peripheral anterior synechiae onto cornea (vertical arrows). S, sclera; CB, ciliary body; PC, posterior chamber; C, cornea; horizontal arrow, proliferative membranes.

TABLE VI: REPORTED CASES OF ANGLE-CLOSURE GLAUCOMA AND RETINOPATHY OF PREMATURITY

AUTHORS	YEAR	AGE AT DIAGNOSIS	JACG/CASES REPORTED	COMMENTS
McCormick and Pratt-Johnson ⁸	1971	<2 yr	4/5	One additional case of PHPV
Pollard ⁸⁰	1980	5 mo to 3.5 yr	5/5	All patients treated with PPV and PPL
Smith and Shivitz ⁸⁵	1984	20-28yr	3/3	
Pollard ¹¹⁷	1984	7 mo to 3 yr	15/15	Only 3 cases described in article
Halperin and Schoch ⁶	1988	4 yr	1/1	Angle closure after scleral buckle
Ueda and Ogino ⁸⁴	1988	22 yr	1/1	
Hartnett et al ⁸⁷	1990	4.5-35 mo	3 of 26 eyes	
Michael et al ⁹	1991	12-45 yr	9/10	
Dhillon et al ¹¹⁸	1992	23 wk	1/1	
Lee et al ⁷⁷	1998	2 yr	1/1	Post diode laser treatment
Chen and Kalina ⁸⁶	1998	38 yr	1/1	Late-onset NVG

JACG, juvenile angle closure glaucoma; NVG, neovascular glaucoma; PHPV, persistent hyperplastic primary vitreous; PPL, pars plana lensectomy; PPV, pars plana vitrectomy.

involved eyes had chronic angle closure with PAS, and all required iridotomies. All continued to require antiglaucoma treatment with multiple medications at last follow-up.

LENS SUBLUXATION

Three of our patients had Weill-Marchesani syndrome. Patients exhibit short stature, brachydactyly, brachycephaly, and microspherophakia. There is severe limitation of mobility of the fingers and wrists to both active and passive motion. The globe is usually normal in size, but two of our patients had nanophthalmos. Lenticular myopia occurs early in the second decade. Lens dislocation is common and also occurs early. In one series, 12 lenses of 10 patients were noted to be dislocated at the initial examination (average age, 20 years), and 2 dislocated subsequently.⁹⁰

Glaucoma may result from either forward movement of the lens or dislocation into the anterior chamber (Table VII). Loosening of zonules permits the lens to move anteriorly, increasing its area of contact with the iris. This results in relative pupillary block, forward bowing of the peripheral iris, and gradual shallowing of the anterior chamber.⁹¹ Chronic angle closure is common. Angle closure caused by microspherophakia often becomes worse with miotic therapy. If iridotomy fails to open an angle and appositional angle closure persists, ALPI may be successful.¹⁶

Marfan syndrome is an autosomal dominant disease of collagen synthesis. Patients are characterized by tall

stature, long digits, and hyperextensible joints. Ocular findings include megalocornea, keratoconus, microspherophakia, lens subluxation, and both open-angle and angle-closure glaucoma (Table VIII).

OTHER ETIOLOGIES

One patient had persistent hyperplastic primary vitreous, which is usually unilateral and is recognizable at birth in full-term infants with leukokoria due to a retrolental fibrovascular mass.⁹² Angle closure can occur as a result of an intumescent cataract, forward movement of the lens-iris diaphragm associated with contracture of the retrolental membrane, or hemorrhage from persistent vessels within the fibrovascular membrane.⁹³ Angle closure in younger patients has also been reported in association with various syndromes not represented in our series (Table IX). These include Turner's syndrome,^{94,95} Alagille syndrome,⁹⁶ childhood cystinosis,¹⁴ oculodentodigital dysplasia,^{97,98} congenital microcoria,^{99,100} and familial exudative vitreoretinopathy.¹⁰¹

CONCLUSION

Persons aged 40 years or younger accounted for 2.34% of our patients with angle closure. Nevertheless, most of the patients were older than age 30 at the time of diagnosis, and angle closure in persons younger than 30, especially children, must still be considered rare. It is possible that

TABLE VII: REPORTED CASES OF ANGLE-CLOSURE GLAUCOMA AND WEILL-MARCHESANI SYNDROME

AUTHORS	YEAR	AGE AT DIAGNOSIS	JACG/CASES REPORTED
Jensen et al ⁹⁰	1974	12-47 yr	8/10
Wright and Chrousos ¹⁰²	1985	6 yr	1/1
Taylor ¹⁰³	1996	NA	1/1
Evereklioglu et al ¹⁰⁴	1999	19-27	2/6

JACG, juvenile angle closure glaucoma; NA, not available.

Angle Closure in Younger Patients

TABLE VIII: REPORTED CASES OF ANGLE-CLOSURE GLAUCOMA AND MARFAN SYNDROME

AUTHORS	YEAR	AGE AT DIAGNOSIS	JACG/CASES REPORTED
Allen et al ¹¹²	1967	9-40 yr	0/6
Izquierdo et al ¹¹³	1992	1-79 yr	2/13
JACG, juvenile angle closure glaucoma .			

TABLE IX: REPORTED CASES OF JUVENILE ANGLE CLOSURE, VARIOUS ETIOLOGIES

AUTHORS	YEAR	JACG/CASES REPORTED	ETIOLOGY
Jones and Watson ⁷	1967	1/1	Phospholine iodide
McCormick and Pratt-Johnson ⁸	1971	5/5	ROP, PHPV
Mills and Robb ¹⁰	1994	3/155	PHPV, congenital rubella
Mori et al ¹¹⁹	1997	2/9	Secondary to PHPV and cataract
Yu and Chang ¹²⁰	1997	1/2	PHPV
Sawada et al ¹²¹	2001	1/1	PHPV
Eibschitz-Tsimhoni et al	1997	1/1	Vogt-Koyanagi-Harada syndrome
Rathinam et al ¹²²	1997	2/3	Vogt-Koyanagi-Harada syndrome
Katsushima et al ¹²³	1996	1/1	Ciliary medulloepithelioma
Potamitis and Felder ¹⁶⁶	1993	1/1	Alagille syndrome
Sharir et al ¹²⁴	1992	1/1	Sneezing, probable elevated episcleral venous pressure
Nash and Lindquist ¹²⁵	1992	1/1	HIV, bilateral choroidal effusions
Kearns and Dhillon ¹²⁶	1990	1/1	Labor
Browning et al ¹²⁷	2000	1/1	Paroxetine therapy
Fivgas and Beck ⁵	1997	1/1	Ocular albinism
Wan et al ¹⁴	1986	1/1	Cystinosis
Vajpayee et al ¹³	1991	16/16	Pseudophakic pupillary block
Appleby and Kinder ¹	1971	1/1	Possible nanophthalmos vs medication-induced
Faberowski et al ¹²⁸	2001	4/4	Congenital pupil-iris-lens membrane, ectopia lentis

JACG, juvenile angle closure glaucoma; PHPV, persistent hyperplastic primary vitreous; ROP, retinopathy of prematurity.

our patient population was skewed away from some diagnoses, such as ROP or uveitis, because of the large number of pediatric ophthalmologists in the New York area.

The mechanisms causing angle closure in younger patients differ in frequency from those in older patients. Young adults with angle closure are most likely to have plateau iris. Iridociliary cysts should be ruled out by UBM. Because angle closure in younger patients is unusual, and because gonioscopy in these patients may not be routinely performed, the clinician must maintain a high index of suspicion. We advocate performing gonioscopy on all patients undergoing initial examination. Prompt treatment with peripheral iridotomy is indicated in these patients. Furthermore, periodic gonioscopy is needed to detect further angle closure requiring iridoplasty to prevent future trabecular meshwork dysfunction, PAS formation, and chronic angle-closure glaucoma.

REFERENCES

1. Appleby RSL, Kinder RSL. Bilateral angle closure glaucoma in a 14-year-old boy. *Arch Ophthalmol* 1971;86:449-450.
2. Boase AJ. Acute glaucoma in an adolescent. *Am J Ophthalmol* 1948;31:997-999.
3. Brosnan JD. Primary chronic angle-closure glaucoma in a young woman of 19 years: a case report. *Trans Asia-Pac Acad Ophthalmol* 1973;4:130-132.
4. Collyer R, Arstikaitis M, Pashby T. Glaucoma in children. *Trans Can Ophthalmol Soc* 1959;21:92.
5. Fivgas GD, Beck AD. Angle-closure glaucoma in a 10-year-old girl. *Am J Ophthalmol* 1997;124:251-253.
6. Halperin LS, Schoch LH. Angle closure glaucoma after scleral buckling for retinopathy of prematurity. Case report. *Arch Ophthalmol* 1988;106:453.
7. Jones DEP, Watson DM. Angle-closure glaucoma precipitated by the use of phospholine iodide for esotropia in a child. *Br J Ophthalmol* 1967;51:783-785.
8. McCormick AQ, Pratt-Johnson JA. Angle-closure glaucoma in infancy. *Can J Ophthalmol* 1971;6:38-41.

9. Michael AJ, Pesin SR, Katz LJ, et al. Management of late-onset angle-closure glaucoma associated with retinopathy of prematurity. *Ophthalmology* 1991;98:1093-1098.
10. Mills MD, Robb RM. Glaucoma following childhood cataract surgery. *J Pediatr Ophthalmol Strabismus* 1994;31:355-360.
11. Shields JA, Shields CL, Lois N, et al. Iris cysts in children: classification, incidence, and management. The 1998 Torrence A. Makley Jr Lecture. *Br J Ophthalmol* 1999;83:334-338.
12. Vajpayee RB, Talwar D. Pseudophakic malignant glaucoma in a child. *Ophthalmic Surg* 1991;22:266-267.
13. Vajpayee RB, Angra SK, Titiyal JS, et al. Pseudophakic pupillary-block glaucoma in children. *Am J Ophthalmol* 1991;111:715-718.
14. Wan WL, Minckler DS, Rao NA, et al. Pupillary-block glaucoma associated with childhood cystinosis. *Am J Ophthalmol* 1986;101:700-705.
15. Shields MD, Ritch R. Classifications and mechanisms of the glaucomas. In: Ritch R, Shields MB, eds. *The Secondary Glaucomas*. St Louis, Mo: CV Mosby, 1982.
16. Ritch R, Solomon LD. Argon laser peripheral iridoplasty for angle-closure glaucoma in siblings with Weill-Marchesani syndrome. *J Glaucoma* 1992;1:243-247.
17. Ritch R, Liebmann J, Tello C. A construct for understanding angle-closure glaucoma: the role of ultrasound biomicroscopy. *Ophthalmol Clin North Am* 1995;8:281-293.
18. Lowe RF. Primary angle-closure glaucoma: a review of ocular biometry. *Aust J Ophthalmol* 1977;5:9-17.
19. Delmarcelle Y, François J, Goes F, et al. Biometrie oculaire clinique (oculometrie). *Bull Soc Belge Ophthalmol* 1976;1:172.
20. Tomlinson A, Leighton DA. Ocular dimensions in the heredity of angle-closure glaucoma. *Br J Ophthalmol* 1973;57:475-486.
21. Lowe RF, Clark BAJ. Posterior corneal curvature: correlations in normal eyes and in eyes involved with primary angle-closure glaucoma. *Br J Ophthalmol* 1973;57:475-478.
22. Lee DA, Brubaker RF, Ilstrup DM. Anterior chamber dimensions in patients with narrow angles and angle-closure glaucoma. *Arch Ophthalmol* 1984;102:46-50.
23. Fontana SC, Brubaker RF. Volume and depth of the anterior chamber in the normal aging human eye. *Arch Ophthalmol* 1980;98:1801-1808.
24. Heim M. Photographische Bestimmung der Tiefe und des Volumens der menschlichen Vorderkammer. *Ophthalmologica* 1941;102:193-220.
25. Weekers R, Delmarcelle Y, Collignon J, et al. Mesure optique de la profondeur de la chambre antérieure. Applications cliniques. *Doc Ophthalmol* 1973;34:413-434.
26. Kondo T, Miura M, Imamichi M. Anterior chamber volume in the normal human eye. *Acta Soc Ophthalmol Jpn* 1985;89:1099-1103.
27. Grosvenor T. Reduction in axial length with age: an emmetropizing mechanism for the adult eye? *Am J Optom Physiol Optics* 1987;64:657-663.
28. Hoffer KJ. Axial dimension of the human cataractous lens. *Arch Ophthalmol* 1993;111:914-918.
29. Markowitz SN, Morin JD. Ratio of lens thickness to axial length for biometric standardization of angle-closure glaucoma. *Am J Ophthalmol* 1985;99:400.
30. Tornquist R. Angle-closure glaucoma in an eye with a plateau type of iris. *Acta Ophthalmol* 1958;36:413.
31. Wand M, Grant WM, Simmons RJ, et al. Plateau iris syndrome. *Trans Am Acad Ophthalmol Otolaryngol* 1977;83:122.
32. Lowe RF, Ritch R. Angle-closure glaucoma: clinical types. In: Ritch R, Shields MB, Krupin T, eds. *The Glaucomas*. St Louis, Mo: CV Mosby, 1989:839-853.
33. Ritch R. Plateau iris is caused by abnormally positioned ciliary processes. *J Glaucoma* 1992;1:23-26.
34. Pavlin CJ, Ritch R, Foster FS. Ultrasound biomicroscopy in plateau iris syndrome. *Am J Ophthalmol* 1992;113:390-395.
35. Ritch R, Liebmann JM. Role of ultrasound biomicroscopy in the differentiation of block glaucomas. *Curr Opin Ophthalmol* 1998;9:39-45.
36. Ritch R, Tran HV, Ishikawa H, et al. Iridociliary apposition in plateau iris syndrome persists after cataract extraction. *Am J Ophthalmol* 2002;(In Press).
37. Ritch R. Argon laser peripheral iridoplasty: an overview. *J Glaucoma* 1992;1:206-213.
38. Ritch R, Liebmann JM. Argon laser peripheral iridoplasty: a review. *Ophthalmic Surg Lasers* 1996;27:289-300.
39. Vela A, Rieser JC, Campbell DG. The heredity and treatment of angle-closure glaucoma secondary to iris and ciliary body cysts. *Ophthalmology* 1984;91:332-337.
40. Tanihara H, Akita J, Honjo M, et al. Angle closure caused by multiple, bilateral iridociliary cysts. *Acta Ophthalmol* 1997;75:216-217.
41. Azuara-Blanco A, Spaeth GL, Araujo SV, et al. Plateau iris syndrome associated with multiple ciliary body cysts. Report of 3 cases. *Arch Ophthalmol* 1996;114:666-668.
42. Bron AJ, Wilson CB, Hill AR. Laser treatment of primary ring-shaped epithelial iris cyst. *Br J Ophthalmol* 1984;68:859-865.
43. Viestenz A, Bergua A, Mardin CY, et al. Acute bilateral angle-closure glaucoma secondary to ciliary body epithelial cysts of the pars plicata: correlation with the ultrasound biomicroscope. *Klin Monatsbl Augenheilkd* 2000;217:127-129.
44. Kuchenbecker J, Motschmann M, Schmitz K, et al. Laser iridocystotomy for bilateral acute angle-closure glaucoma secondary to iris cysts. *Am J Ophthalmol* 2000;129:391-393.
45. Marigo FA, Esaki K, Finger PT, et al. Differential diagnosis of anterior segment cysts by ultrasound biomicroscopy. *Ophthalmology* 1999;106:2131-2135.
46. Thomas R, Mulligan N, Aylward GW, et al. Angle closure glaucoma due to iris and ciliary body cysts. *Aust N Z J Ophthalmol* 1989;17:317-319.
47. Ritch R, Lowe RF. Angle-closure glaucoma: clinical types. In: Ritch R, Shields MB, Krupin T, eds. *The Glaucomas*. 2nd ed. St Louis, Mo: CV Mosby, 1996:823-840.
48. O'Grady RB. Nanophthalmos. *Am J Ophthalmol* 1971;71:1251.
49. Simmons RB, Montenegro MH, Simmons RJ. Primary angle closure glaucoma. In: Tasman W, Jaeger EA, eds. *Duane's Ophthalmology*. Philadelphia: Lippincott Williams & Wilkins, 1996:1-43.
50. Singh O, Simmons RJ, Brockhurst RJ, et al. Nanophthalmos. A perspective on identification and treatment. *Ophthalmology* 1982;89:1006-1012.

51. Uyama M, Takahashi K, Kozaki J, et al. Uveal effusion syndrome. Clinical features, surgical treatment, histologic examination of the sclera and pathophysiology. *Ophthalmology* 2000;107:441-449.
52. Fukuchi T, Abe H, Sawaguchi S. Collagen fibrils in nanophthalmic sclerae. *J Jpn Ophthalmol Soc* 2000;104:706-710.
53. Yamani A, Wood I, Sugino I, et al. Abnormal collagen fibrils in nanophthalmos: a clinical and histologic study. *Am J Ophthalmol* 1999;127:106-108.
54. Forrester JV, Lee WR, Kerr PR, et al. The uveal effusion syndrome and trans-scleral flow. *Eye* 1990;4:354-365.
55. Shiono T, Shoji A, Mutoh T, et al. Abnormal sclerocytes in nanophthalmos. *Graefes Arch Clin Exp Ophthalmol* 1992;30:348-351.
56. Stewart DHI, Streeten BW, Brockhurst RJ, et al. Abnormal scleral collagen in nanophthalmos. An ultrastructural study. *Arch Ophthalmol* 1991;109:1017-1025.
57. Kawamura M, Tajima S, Azuma N, et al. Biochemical studies of glycosaminoglycans in nanophthalmic sclera. *Graefes Arch Clin Exp Ophthalmol* 1995;233:58-62.
58. Kawamura M, Tajima S, Azuma N, et al. Immunohistochemical studies of glycosaminoglycans in nanophthalmic sclera. *Graefes Arch Clin Exp Ophthalmol* 1996;234:19-24.
59. Yue BY, Duvall J, Goldberg MF, et al. Nanophthalmic sclera. Morphologic and tissue culture studies. *Ophthalmology* 1986;93:534-541.
60. Brockhurst RJ. Nanophthalmos with uveal effusion: a new clinical entity. *Arch Ophthalmol* 1975;93:1289-1299.
61. Allen KM, Meyers SM, Zegarra H. Nanophthalmic uveal effusion. *Retina* 1988;8:145-147.
62. Good WV, Stern WH. Recurrent nanophthalmic uveal effusion syndrome following laser trabeculoplasty. *Am J Ophthalmol* 1988;106:234-235.
63. Han LR, Cairns JD. Nanophthalmos with longstanding choroidal effusion and serous retinal detachment. *Aust N Z J Ophthalmol* 1997;25:181-183.
64. Ryan EA, Zwaan J, Chylack LT. Nanophthalmos with uveal effusion. Clinical and embryologic considerations. *Ophthalmology* 1982;89:1013-1017.
65. Lesnoni G, Rossi T, Nistri A, et al. Nanophthalmic uveal effusion syndrome after prophylactic laser treatment. *Eur J Ophthalmol* 1999;9:315-318.
66. MacKay CJ, Shek MS, Carr RE, et al. Retinal degeneration with nanophthalmos, cystic macular degeneration, and angle closure glaucoma: a new recessive syndrome. *Arch Ophthalmol* 1987;105:366-371.
67. Hermann P. Le syndrome microphthalmie-rétinite pigmentaire-glaucome. *Arch Ophthalmol (Paris)* 1958;18:17.
68. Ghose S, Sachdev MS, Kumar H. Bilateral nanophthalmos, pigmentary retinal dystrophy, and angle closure glaucoma—a new syndrome? *Br J Ophthalmol* 1985;69:624.
69. Buys YM, Pavlin CJ. Retinitis pigmentosa, nanophthalmos, and optic disc drusen. A case report. *Ophthalmology* 1999;106:619-622.
70. Hatcher WF. Extreme axial hyperopia. *Arch Ophthalmol* 1952;48:161-162.
71. Altintas AK, Acar MA, Yalvaç IS, et al. Autosomal recessive nanophthalmos. *Acta Ophthalmol* 1997;75:325-328.
72. Cross HE, Yoder F. Familial nanophthalmos. *Am J Ophthalmol* 1976;81:300-306.
73. Blodi F. Symposium: Retrolental fibroplasia (retinopathy of prematurity) management. *Trans Am Acad Ophthalmol Otolaryngol* 1955;59:35-38.
74. Hartnett ME, Gilbert MM, Hirose T, et al. Glaucoma as a cause of poor vision in severe retinopathy of prematurity. *Graefes Arch Clin Exp Ophthalmol* 1993;231:433-438.
75. Gordon RA, Donzis PB. Myopia associated with retinopathy of prematurity. *Ophthalmology* 1986;93:1593.
76. Ginsberg J, Bove KE. Ocular pathology of trisomy 13. *Ann Ophthalmol* 1974;6:113.
77. Lee GA, Lee LR, Gole GA. Angle-closure glaucoma after laser treatment for retinopathy of prematurity. *J Am Assoc Pediatr Ophthalmol Strabismus* 1998;2:383-384.
78. Cohen J, Alfano JE, Boshes LD, et al. Clinical evaluation of school age children with retrolental fibroplasia. *Am J Ophthalmol* 1964;57:41-57.
79. Hittner HM, Rhodes LM, McPherson AR. Anterior segment abnormalities in cicatricial retinopathy of prematurity. *Ophthalmology* 1979;86:803-816.
80. Pollard ZF. Secondary angle-closure glaucoma in cicatricial retrolental fibroplasia. *Am J Ophthalmol* 1980;89:651-653.
81. Laws DE, Haslett R, Ashby D, et al. Axial length biometry in infants with retinopathy of prematurity. *Eye* 1994;8:427-430.
82. Kushner BJ. Ciliary block glaucoma in retinopathy of prematurity. *Arch Ophthalmol* 1982;100:1078-1079.
83. Walton DS. Retrolental fibroplasia with glaucoma. In: Chandler DA, Grant WM, ed. *Glaucoma*. 2nd ed. Philadelphia: Lea & Febiger, 1979.
84. Ueda N, Ogino N. Angle-closure glaucoma with pupillary block mechanism in cicatricial retinopathy of prematurity. *Ophthalmologica* 1988;196:15-18.
85. Smith J, Shivitz I. Angle-closure glaucoma in adults with cicatricial retinopathy of prematurity. *Arch Ophthalmol* 1984;102:371-372.
86. Chen PP, Kalina RE. Chronic angle-closure mimicking rubeotic glaucoma in an adult with retinopathy of prematurity. *Arch Ophthalmol* 1998;116:1248.
87. Hartnett ME, Gilbert MM, Richardson TM, et al. Anterior segment evaluation of infants with retinopathy of prematurity. *Ophthalmology* 1990;97:122-130.
88. Kelly SP, Fielder AR. Microcornea associated with retinopathy of prematurity. *Br J Ophthalmol* 1987;71:201.
89. Kalina RE. Treatment of retrolental fibroplasia. *Surv Ophthalmol* 1980;24:229-236.
90. Jensen AD, Cross HE, Paton D. Ocular complications in the Weill-Marchesani syndrome. *Am J Ophthalmol* 1974;77:261.
91. Ritch R. Glaucoma secondary to lens intumescence and dislocation. In: Ritch R, Shields MB, eds. *The Secondary Glaucomas*. St Louis, Mo: CV Mosby, 1982:131-149.
92. Cantor LB. Glaucoma associated with congenital disorders. In: Ritch R, Shields MB, Krupin T, eds. *The Glaucomas*. 2nd ed. St Louis, Mo: CV Mosby, 1996:925-954.
93. Alward WLM, et al. PHPV with glaucoma presenting in infancy. *Arch Ophthalmol* 1991;109:1063.
94. Buckley CA, Cheng H. Intraocular melanoma, diabetes, and Turner's syndrome: presentation with proptosis. *Br J Ophthalmol* 1981;65:460.

95. Khodadoust A, Paton D. Turner's syndrome in a male: report of a case with myopia, retinal detachment, cataract, and glaucoma. *Arch Ophthalmol* 1967;77:630.
96. Potamitis T, Felder AR. Angle-closure glaucoma in Alagille syndrome. A case report. *Ophthalmic Paediatr Genet* 1993;14:101-104.
97. Kadrnka-Lovrencé M, et al. Die oculo-dento-digitale Dysplasie (das Meyer-Schwickerath syndrom). *Monatsschr Kinderheilkd* 1973;121:42.
98. Sugar HS. Oculodentodigital dysplasia syndrome with angle closure glaucoma. *Am J Ophthalmol* 1978;86:36.
99. Hyams SW, Neumann E. Congenital microcoria and combined mechanism glaucoma. *Am J Ophthalmol* 1969;68:326.
100. Veirs ER, Brown W. Congenital miosis. *Arch Ophthalmol* 1961;65:83.
101. Azuara-Blanco A, Pesin SR, Katz LJ, et al. Familial exudative vitreoretinopathy associated with nonneovascular chronic angle-closure glaucoma. *J Glaucoma* 1997;6:47-49.
102. Wright KW, Chrousos GA. Weill-Marchesani syndrome with bilateral angle closure glaucoma. *J Pediatr Ophthalmol Strabismus* 1985;22:129.
103. Taylor JN. Weill-Marchesani syndrome complicated by secondary glaucoma. Case management with surgical lens extraction. *Aust N Z J Ophthalmol* 1996;24:275-278.
104. Evereklioglu C, Hepser IF, Mandi ER. Weill-Marchesani syndrome in three generations. *Eye* 1999;13:773-777.
105. Calhoun FP. The management of glaucoma in nanophthalmos. *Trans Am Ophthalmol Soc* 1975;73:97.
106. Kimbrough RL, Trempe CS, Brockhurst RJ, et al. Angle-closure glaucoma in nanophthalmos. *Am J Ophthalmol* 1979;88:572.
107. Diehl DLC, Feldman F, Tanzer H, et al. Nanophthalmos in sisters, one with exfoliation syndrome. *Can J Ophthalmol* 1989;24:327-330.
108. Kocak I, Altintas AG, Yalvac IS, et al. Treatment of glaucoma in young nanophthalmic patients. *Int Ophthalmol* 1996-97;20:107-111.
109. Flowers CW Jr, Reynolds D, Irvine JA, et al. Pupillary block, angle-closure glaucoma produced by an anterior chamber air bubble in a nanophthalmic eye. *Arch Ophthalmol* 1996;114:1143-1144.
110. Caronia RM, Sturm RT, Fastenberg DM, et al. Bilateral secondary angle-closure glaucoma as a complication of anticoagulation in a nanophthalmic patient. *Am J Ophthalmol* 1998;126:307-309.
111. Othman MI, Sullivan SA, Skuta GL, et al. Autosomal dominant nanophthalmos (NNO1) with high hyperopia and angle closure glaucoma maps to chromosome 11. *Am J Hum Genet* 1998;63:1411-1418.
112. Allen RA, Straatsma BR, Apt L, et al. Ocular manifestations of the Marfan syndrome. *Trans Am Acad Ophthalmol Otolaryngol* 1967;71:18.
113. Izquierdo NJ, Traboulsi EI, Enger C, et al. Glaucoma in the Marfan syndrome. *Trans Am Ophthalmol Soc* 1992;90:111-122.
114. Chandler PA, Braconier HE. Spontaneous intra-epithelial cysts of iris and ciliary body with glaucoma. *Am J Ophthalmol* 1958;45:64.
115. Shields JA, Kline MW, Augsburger JJ. Primary iris cysts: a review of the literature and report of 62 cases. *Br J Ophthalmol* 1984;68:152-166.
116. Lois N, Shields CL, Shields JA, et al. Primary cysts of the iris pigment epithelium. Clinical features and natural course in 234 patients. *Ophthalmology* 1998;105:1879-1885.
117. Pollard ZF. Lensectomy for secondary angle-closure glaucoma cicatricial retrolental fibroplasia. *Ophthalmology* 1984;91:395-398.
118. Dhillon B, Wright E, Laing I, et al. Cryotherapy for retinopathy of prematurity in a regional neonatal intensive care unit. *J Royal Coll Surg Edinb* 1992;37:83-88.
119. Mori M, Keech RV, Scott WE. Glaucoma and ocular hypertension in pediatric patients with cataracts. *J Am Acad Pediatr Ophthalmol Strabismus* 1997;1:98-101.
120. Yu YS, Chang BL. Persistent hyperplastic primary vitreous in male twins. *Korean J Ophthalmol* 1997;11:123-125.
121. Sawada H, Fukuchi T, Ohta A, et al. [Persistent hyperplastic primary vitreous—a case report of adult onset acute angle-closure glaucoma]. *Nippon Ganka Gakkai Zasshi* 2001;105:711-715.
122. Rathinam SR, Namperumalsamy P, Nozik RA, et al. Angle closure glaucoma as a presenting sign of Vogt-Koyanagi-Harada syndrome. *Br J Ophthalmol* 1997;81:608-609.
123. Katsushima H, Suzuki J, Adachi J, et al. Non-rubeotic angle-closure glaucoma associated with ciliary medullo-epithelioma. *Jpn J Ophthalmol* 1996;40:244-250.
124. Sharir M, Huntington AC, Nardin GF, et al. Sneezing as a cause of acute angle-closure glaucoma. *Ann Ophthalmol* 1992;24:214-215.
125. Nash RW, Lindquist TD. Bilateral angle-closure glaucoma associated with uveal effusion: presenting sign of HIV infection. *Surv Ophthalmol* 1992;36:255-258.
126. Kearns PP, Dhillon BJ. Angle-closure glaucoma precipitated by labour. *Acta Ophthalmol* 1990;68:225-226.
127. Browning AC, Reck AC, Chisholm IH, et al. Acute angle-closure glaucoma presenting in a young patient after administration of paroxetine. *Eye* 2000;14:406-408.
128. Faberowski N, Green J, Walton DS. Angle closure in children. *Int Ophthalmol Clin* 2001;41:35-41.

DISCUSSION

DR LOUIS B. CANTOR. The authors present a wealth of information from their large clinical practice regarding angle-closure glaucoma in younger patients. Few articles address angle-closure glaucoma in this population and none have the variety of cases presented by the authors.

Several factors may predispose to angle-closure glaucoma. The incidence of angle-closure glaucoma varies significantly among different races and ethnic populations. While narrow angles may be found in approximately 2% of the Caucasian population, the risk of angle-closure glaucoma is small. The highest incidence of angle-closure glaucoma is in Eskimos whose risk is 30 to 40 times that of the Caucasian population. Angle-closure

glaucoma is less common among African Americans, but more common in Asians. Gender is also an important factor. Women of all races develop angle-closure glaucoma three to four times more often than men. In general, women seem to have shallower anterior chambers, small corneal diameters, and a greater lens thickness. Age, as will be discussed in more detail, is a significant risk factor for angle-closure glaucoma, and the risk of angle closure increases with age. Typically, angle-closure glaucoma occurs in eyes with hyperopia, though it may occur in eyes with any type of refractive error. In hyperopic eyes the anterior chamber depth and volume are generally smaller than in myopic eyes. Characteristics of the anterior chamber also seem to be inherited in a multifactorial fashion. Shallow anterior chambers with occludable angles may occur in first-degree relatives, with an increased risk four to six times over the general population.

Age appears to be one of the most significant predisposing factors to angle-closure glaucoma. With aging and normal lens growth, the anterior chamber decreases in depth and in volume. Because of these changes the prevalence of angle-closure glaucoma in Caucasian populations peaks between 55 to 65 years of age, and it is unusual to see angle-closure glaucoma before the age of 50. In the paper just presented, the authors looked at a unique population of patients diagnosed with angle-closure glaucoma before the age of 40. Of their extensive patient database, they discovered nearly 3,000 patients with angle-closure glaucoma representing approximately 20% of their total patient population. This would be consistent with the general population in the United States. Of these, only 67 patients met their inclusion criteria, which was only 0.48% of their total population, or only just over 2% of the angle closure glaucoma patients in their practice. The majority of these patients were female, which is typical because angle-closure glaucoma is three to four times more common in females.

The median age at diagnosis in this study was 31.5 years. Of significant interest was that 53%, or 35 patients, had plateau iris, whereas in the typical older population, approximately 90% of patients with angle-closure glaucoma will have pupillary block. This represents a very distinct difference, and only two patients in this younger population, representing a very small number of the total population, actually presented with pupillary block as the mechanism for their glaucoma.

While the authors present a very interesting overview of angle-closure glaucoma in younger individuals, many questions remain to be explored. Perhaps most important is what factors predisposed these younger patients to angle-closure glaucoma. Further information regarding the ocular status and dimensions in these younger individuals, such as corneal diameter, corneal curvature, ante-

rior chamber depth, lens thickness, axial length, lens curvature, iris insertion, ciliary body position, or other factors in these eyes, might help explain why the differences in types of glaucoma seen were identified. In addition it would be of interest to know how young patients respond to initial therapy and if they respond the same as or differently than older individuals. We do not know the long-term prognosis in these patients, though one would suspect that they would be more difficult to control with time.

Finally, was there something in the family history or racial characteristics of these patients that might have suggested that they were predisposed to angle-closure glaucoma, or might there be other ways to suspect which of these rare individuals might be at risk for developing glaucoma?

The authors are to be commended for helping to define an uncommon, though potentially serious, ocular condition that can affect younger individuals.

DR JAMES C. BOBROW. In a study published in the *American Journal of Ophthalmology* years ago about our experience with angle-closure glaucoma, we discovered that the average age of our patients was somewhere between 68 and 69. The numbers under the age of 40 were approximately 2.5% to 3% of the population. When we talk about angle closure, we talk about the diagnosis based on gonioscopy and appositional closure, but we don't talk about presenting as acute angle-closure glaucoma. Acute angle-closure glaucoma has decreased by almost 70% over the last several years and is now a rare event. We also looked at predisposing factors. Hyperopia and a keratometry reading of 42 diopters or less were significant.

DR ALLAN J. FLACH. You mentioned that your Weill-Marchesani patients respond very poorly to miotics, with all of that tension created in the sphincter. Have you had experience using the alpha-blockers, like either extemporaneously prepared thymoxamine or the commercially available dapiprozale, which would kind of ignore the sphincter and relax the dilator muscle and perhaps offer a beneficial effect in angle closure in those patients?

DR ALBERT W. BIGLAN. There were no aniridics in this series. The traditional treatment of angle closure with an iridotomy or iridectomy may not be appropriate in the patient with ROP. The mechanism there appears to be a shallowing of the anterior chamber, and lensectomy may be a way of managing this because the lens is pushing the iris forward.

DR WILLIAM TASMAN. I remember one young girl with

ROP who, while studying, noticed that her vision blurred; when she put her head back it cleared. I sent her to Dr Spaeth, who cured her with an iridectomy. More recently we've looked at 25 10-year-olds who had cryo to one eye and laser to the other. We measured with ultrasound biomicroscopy and found that the anterior chambers were shallower in the cryo eyes and the lenses were thicker. I look at them as potential candidates for perhaps angle closure in the future.

DR ROBERT RITCH. In our population, relative pupillary block accounts for about 90% of the angle closure and plateau iris or mixed plateau iris with relative pupillary block accounts for about 7%. Lens-induced angle closure, malignant glaucoma, and secondary angle-closure glaucoma account for about 3%. Plateau iris is much more common in Asia, representing nearly 30% of glaucoma diagnoses. In China, where angle closure is more common than open-angle glaucoma, there seems to be more of a lens-induced component. In Japan, on the other hand, angle closure accounts for a relatively small amount of the total glaucoma. Plateau iris is more common in women and tends to be familial. I wonder if it is a distinct entity or one end of a spectrum with pure relative pupillary block at one end and pure plateau iris in a young patient with no component of pupillary block at the other end.

I certainly agree with Dr Bobrow that acute angle-closure glaucoma has decreased markedly. I would suggest a 90% decrease in incidence. Ophthalmologists are performing gonioscopy more routinely, patients with narrow angles undergo iridotomy earlier, and cataracts are removed earlier.

Patients with Weill-Marchesani syndrome, micro-

spherophakia, and zonular weakening can respond to miotics paradoxically. If the lens is subluxed and the zonules are totally broken, miotics will open the angle, while cycloplegics allow the lens to dislocate into the anterior chamber. If intact zonules remain, cycloplegics will deepen the anterior chamber, while miotics, which contract the ciliary muscle, allow the lens to move anteriorly and worsen the angle closure. The UBM may be helpful. Thymoxamine is no longer available. We found that dapiprozale caused a lot of red eyes and patients hated it. We did not include aniridia in this series because it is not true angle closure. The iris stump slides up onto the trabecular meshwork.

Dr Tasman is correct in that patients, especially children, with ROP need to be watched for the development of angle closure. Many of the younger patients present with acute angle closure because gonioscopy in children may be difficult and the condition missed, but it is important to perform, even if an examination under anesthesia is required. A number of different mechanisms can be responsible, such as lenticular myopia shallowing the anterior chamber, proliferative fibrovascular membranes causing anterior rotation of the lens-iris diaphragm, or after cyclophotocoagulation or scleral buckling. Older patients with ROP can develop pupillary block or chronic angle closure. I don't like taking the lenses out for angle-closure if I can get away with an iridoplasty. In patients with lens-induced angle closure, where the lens is pushing forward, its effect may be transient, but it should be tried. We had a monocular 5-year-old girl with ROP who underwent combined iridotomy and iridoplasty and did well for 7 years before needing a trabeculectomy.